


THE EFFICACY OF GASTROINTESTINAL ENDOSCOPY FOR DIAGNOSIS OF THE SURGICAL GASTRIC PATHOLOGIES			Healthcare
		Keywords: Endoscopy, vomiting, analysis, gastrointestinal, submucosal.	
Elta HASA	Veterinary Hospital, Kombinat, Tirana, Albania.		
Erinda LIKA	Agricultural University of Tirana, Faculty of Veterinary Medicine, Department of Clinical Subjects, Tirana, Albania.		
Paskal GJINO	Agricultural University of Tirana, Faculty of Veterinary Medicine, Department of Clinical Subjects, Tirana, Albania.		

Abstract

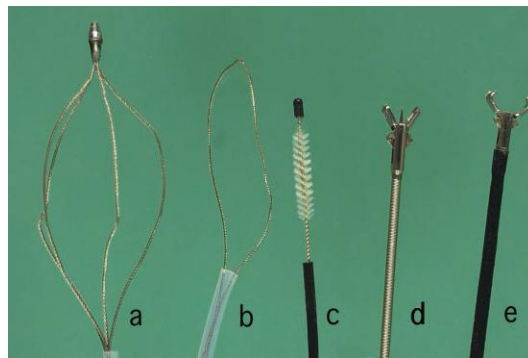
Gastrointestinal endoscopy for small animals has evolved to become both an important diagnostic option and, in some situations even a therapeutic solution. Once considered to be only an adjunct to other diagnostic means, gastrointestinal endoscopy is now one of the most important techniques for evaluating patients with gastrointestinal signs. The minimal invasiveness, the increasing diagnostic capabilities, and the professional enjoyment in performing endoscopic procedures all add to the popularity of endoscopy in small animal practice. Endoscopy lends itself to a role of gastrointestinal evaluation because it provides visual documentation of the gastrointestinal lumen and the ability to collect samples for analysis, remove foreign bodies. Often other diagnostic test such as barium contrast studies or ultrasound evaluation of the gastrointestinal tract may not be sensitive enough to delineate many gastrointestinal mucosal disorders and fail to provide a means of collecting tissue for analysis. The gastrointestinal endoscopy has been performed for the first time in Petlife Hospital and the Veterinary Medicine Faculty of Tirana District in 12 dogs of different breeds, gender and age. All these dogs have exhibited clinical signs as anorexia, constipation, diarrhea, dysphagia, hematemesis, melena, mucoid feces, nausea, regurgitation, salivation tenesmus, vomiting and weight loss. Through gastric endoscopy was performed visual examination of the mucosal surface. The potential limitation of gastrointestinal endoscopy was the inability to diagnose submucosal lesions, gastrointestinal motility disorders or lesions that couldn't be reached by endoscope. In 5 cases have been removed esophageal and gastric foreign bodies. In 2 adult dogs were identified the presence of gastric tumors. All the animals that have been examined through endoscopy were sedated with sedatives. As a conclusion the gastroscopy endoscopy remains in our days one of the most efficient diagnostic way of many surgical gastric pathologies.

Introduction

The basic gastrointestinal endoscope system consists of two components: the fiber optic endoscope and a light source. Fiber optics in the endoscope are simply bundles of tiny glass fibers that function in transporting either light for illumination or for transmitting images. To enable image transmission, the very small-diameter glass fibers are coherently packed into bundles that transmit an image to the eyepiece in the endoscope. Although each fiber produces only an extremely tiny point of uniform light and color, when the fibers are viewed together as a unit, an image is observed. The size of individual fibers, compactness of fiber bundles, and accuracy of coherent bundle relationship determine the sharpness of the image. Fiber bundles are quite fragile, however, and can be damaged by improper handling. If a glass fiber is broken, then it will not transmit light and is seen as a black dot when looking through the viewing lens. The lens system at the proximal end of the image bundle magnifies the image for operator viewing. A video camera is attached to the eyepiece and the image viewed on a video monitor. Illumination fiber optics are randomly grouped glass fibers that transmit light originating from a high-intensity light source housed outside the patient. The light source that illuminates the endoscope is either a halogen or the preferred xenon light.

Many gastrointestinal video endoscopes now incorporate the same illumination fiber optics used previously, but the image is recorded by a small microelectric video chip located in the distal tip of the endoscope. The image is then transmitted electronically to a video processor and viewed on a television monitor. These more current model endoscopes provide superior images but are also more costly. The basic fiber optic endoscope consists of three sections: the insertion tube, the handpiece, and the umbilical cord.

A number of flexible instruments are available for use with an endoscope. Basic instruments suggested for small animal endoscopy include a biopsy forceps, foreign-body grasping instruments (baskets, snares, claws), and cytology brushes. Other available instruments include aspiration tubes, injection needles, and coagulation electrodes.



Examples of basic endoscopic instruments: (a) wire basket, (b) wire snare, (c) cytology brush, (d) foreign body grasper with spike, and (e) foreign body grasper.

The gastrointestinal endoscopy has been performed for the first time in Petlife Hospital and the Veterinary Medicine Faculty of Tirana District in 12 dogs of different breeds, gender and age. All these dogs have exhibited clinical signs as anorexia, constipation, diarrhea, dysphagia, hematemesis, melena, mucoid feces, nausea, regurgitation, salivation tenesmus, vomiting and weight loss. Through gastric endoscopy was performed visual examination of the mucosal surface. The potential limitation of gastrointestinal endoscopy was the inability to diagnose submucosal lesions, gastrointestinal motility disorders or lesions that couldn't be reached by endoscope. In 5 cases have been removed esophageal and gastric foreign bodies. In 2 adult dogs were identified the presence of gastric tumors. All the animals that have been examined through endoscopy were sedated with sedatives. As a conclusions the gastroscopy endoscopy remains in our days one of the most efficient diagnostic way of many surgical gastric pathologies.

Material and Methods

Before performing upper gastrointestinal endoscopy, the patients have been fasted for at least 12 to 24 hours. This restriction was important because the presence of food in the stomach makes gastric evaluation almost impossible. Patients with gastric disease often have altered motility, and a standard 12-hour fast may be insufficient.

Anesthesia was required for a gastrointestinal endoscopy, because the procedure may cause discomfort and dogs are unlikely to be cooperative during such as test. In addition, if the dog doesn't sit still, he may damage the equipment used, which is quite pricey. The anesthetic was administered approximately 15 to 30 minutes prior to the test and was effective for a number of hours after the gastrointestinal endoscopy.

General anesthesia with a cuffed endotracheal tube was performed for all endoscopic procedures. This setup prevents damage to the endoscope and minimizes the chance of aspiration. An oral speculum was always in place to prevent the patient from biting the endoscope, For routine upper or lower endoscopy, the patient was placed in left lateral recumbence. This position was ideal for visualization of the pylorus and entry into the duodenum. The equipment was closed to the operator left hand (holding the handpiece) and the patient was close to their right hand (holding the insertion tube). This position allows the endoscopist to simultaneously control the deflection knobs on the handpiece and the movement of the insertion tube without crossing lines or limbs. The monitor was placed in a position that the operator could comfortably look directly at the screen.

The majority of upper GI endoscopic procedures are done with the patient in left lateral recumbence, with the patient's head and neck extended and a mouth speculum placed to protect endoscope. The endoscope is passed through the oral pharynx and into the upper esophageal sphincter. Resistance may be encountered if the scope is directed into one of the piriform recesses located on either side of the larynx. When the scope is in the proximal portion of the esophagus, the lumen is insufflated with air. During the examinations of 4 our patients that exhibit disorders of gastrointestinal tract was detected grossly detectable defects in the gastric mucosa. This definition is expanded to include gastric erosions, which most often were appeared as multiple, small, superficial mucosal erosions

Gastric tumors were diagnosed in two dogs of middle aged. The type of the gastric tumor was not identified because of the leak of the histopathological examinations. The tumors maes were also ulcerated. In 5 cases have been removed esophageal and gastric foreign bodies.

Results and Discussion

Gastrointestinal endoscopy has evolved to become one of the most important techniques available for evaluating patients with evidence of a primary gastrointestinal abnormality or disease. Endoscopy requires anesthesia but is minimally invasive and only rarely associated with any degree of morbidity, much less mortality. With experience, the majority of endoscopic procedures are performed quickly and efficiently, require modest preparation and support staff, and yet frequently have the potential to provide a definitive diagnosis. In the case of esophageal strictures or esophageal or gastric foreign bodies, endoscopy may even be a curative undertaking. Endoscopy allows for direct visualization of a large part of the gastrointestinal tract, directed

collection of multiple mucosal biopsy samples, brush cytology and fluid aspiration, and therapeutic procedures such as esophageal and gastric foreign body removal and esophageal stricture dilation. Although it requires Endoscopy frequently follows abdominal ultrasound in the advanced diagnostic workup of gastrointestinal cases. Although the two modalities have distinctly different diagnostic capabilities, they can often complement each other, and ultrasound is frequently useful in the decision-making process during a diagnostic workup.

Gastrointestinal endoscopy does have a number of important limitations that need to be considered. These are based, in part, on the physical characteristics of the scope both diameter and insertion tube length and on the size of the animal being examined. The length of the endoscope is a limiting factor in how far the scope can be passed through the small intestine. There is also a limit to the size and depth of biopsies taken from the gastrointestinal wall. Sample taking is generally confined to the mucosa; consequently submucosal or deeper lesions are missed. There is also some restriction in the size of gastrointestinal foreign bodies that can be removed relative to the shape of the foreign object and the type of grasping forceps available.

Endoscopy does not allow for evaluation of the entire length of the gastrointestinal tract. The oral cavity, esophagus, stomach, and proximal small intestine are accessible in the vast majority of veterinary patients regardless of size, with the appropriate equipment; this constitutes an “upper GI.” The rectum, colon, and cecum can be reached in the majority of patients (simply termed *colonoscopy* or “lower GI”), and a biopsy instrument (rarely the scope itself) can be passed from the colon through the ileocecal junction to obtain “blind” samples from the distal portion of the ileum. That leaves a significant length of jejunum and ileum that is not accessible by endoscopy. Focal disease in that portion of the intestine (as identified by abdominal ultrasound, for example) does not lend itself to endoscopic evaluation. Several recent studies have found that in a small number of patients gastrointestinal neoplasia was found in the distal ileum and jejunum without being present in the duodenum. The most important limitation of GI endoscopy, however, is the inability to biopsy the submucosa, much less obtain full-thickness biopsies. Again, this becomes particularly relevant in cases in which neoplasia is on top of the list of differentials. It may also be important in cases in which lymphangiectasia is a prominent component of the disease process. Some degree of lymphatic lacteal dilation would be expected in the villi in patients with inflammatory bowel disease, but submucosal dilation is more consistent with lymphangiectasia being the primary disease process. Gastrointestinal endoscopy is not the test of choice for the diagnosis of megaesophagus, although it can be used to assess esophageal erosions or ulceration secondary to regurgitation. Endoscopy is also not useful for the diagnosis of gastrointestinal motility disorders, although again it can be used to assess esophageal damage secondary to reflux disease. Given these limitations, gastrointestinal endoscopy remains an integral part of the workup of many cases involving signs consistent with primary gastrointestinal disease. Endoscopy is usually performed when a patient shows clinical signs, such as vomiting, diarrhea, ptyalism, melena, or hematochezia, or there is laboratory, radiographic, or ultrasound evidence of esophageal, gastric, duodenal, or colonic abnormalities. Esophageal and gastric

foreign body removal with an endoscope is now preferred to surgical intervention because of the minimal invasiveness of the procedure. Endoscopy is also the preferred method for gastrostomy tube placement, although non-endoscopic placement techniques have been described.

Conclusions and Recommendations

The endoscope should not be advanced “blindly” without visualization of the lumen. If the lumen does not distend with insufflations, manual compression of the esophagus just below the larynx prevents air from escaping out the upper esophageal sphincter.

Insufflations of a perforated esophagus results in air being forced into the chest cavity creating a tension pneumothorax, so any patient with a possible esophageal perforation must be approached cautiously. The esophagus should distend easily and the longitudinal folds flatten and become smooth. There should be little fluid within the lumen, other than a small amount of swallowed saliva. Complications associated with gastrointestinal endoscopy are rare. Although endoscopy is considered to be a minimally invasive procedure, it does require general anesthesia. Organ perforation is a potentially catastrophic complication but is extremely rare as long as the basic principles of endoscopy are followed. The most common endoscopic complication is a consequence of overdistention of the stomach with insufflated air. Excessive gaseous distention of the stomach can result in hypotension and compromised respiratory function. This problem is prevented by vigilant awareness of the degree of gastric distention and close anesthetic monitoring.

References

1. Tams, T. R. *Small Animal Endoscopy*. St Louis: The CV Mosby Company, 1990: 417.
2. Simpson, K. W. Gastrointestinal endoscopy in the dog. *Journal of Small Animal Practice* 1993; 34: 180–188.
3. Sullivan, M., Miller, A. Endoscopy of the oesophagus and stomach in the dog with persistent regurgitation and vomiting. *Journal of Small Animal Practice* 1985; 26: 369–379.
4. Lecoinde, P., Cadore, J. L. Les affections de l'oesophage des carnivores domestiques. *Pratique Médicale et Chirurgicale de l'Animal de Compagnie* 1994; 29: 25–43.
5. Lecoinde, P. Apport de l'endoscopie dans le diagnostic des affections de l'estomac du chien (115 cas). *Pratique Médicale et Chirurgicale de l'Animal de Compagnie* 1994; 5: 471–477.
6. Lecoinde, P., Chevallier, M. Aspect endoscopique et histologique des gastrites chroniques du chien. Proposition d'une classification. *Pratique Médicale et Chirurgicale de l'Animal de Compagnie* 1995; 2: 421–428.
7. Gualtieri, M., Monzeglio, M. G., Scanziani, E., Domeneghini, C. Pyloric hyperplastic polyps in the French Bulldog. *Veterinaria* 1994; 8: 33–42.
8. Leib, M., Saunders, G., Moon, M. Endoscopic diagnosis of chronic hypertrophic pyloric gastropathy in dogs. *Journal of Veterinary Internal Medicine* 1993; 7: 335–341.

9. Grooters, A., Johnson, S. Canine gastric leiomyoma. *Compendium on Continuing Education* 1995; 17: 1485–1491.
10. Scanziane, E., Giusti, A. M., Gualtieri, M., Fonda, D. Gastric carcinoma in the Belgian Shepherd dog. *Journal of Small Animal Practice* 1991; 32: 465–469.
11. Grooters, A., Sherding, R., Johnson, S., Paola, L. P. Endoscopy case of the month: chronic vomiting and weight loss in a dog. *Veterinary Medicine* 1993; 88: 1128–1132.
12. Lecoindre, P., Chevallier, M. Findings on endo-ultrasonographic (EUS) and endoscopic examination of gastric tumour in dogs. *European Journal of Comparative Gastroenterology* 1997; 2: 21–27.
13. Hart, J. R., Shaker, E., Patnaik, A. K., Garvey, M. S. Lymphocytic plasmacytic enterocolitis in cats: 60 cases (1988–1990). *Journal of the American Animal Hospital Association* 1994; 30: 505–514.
14. Lecoindre, P., Chevallier, M. Contribution to the study of feline inflammatory bowel disease: 51 cases (1991–1994). *Review Medicine Veterinaire* 1997; 148: 893–902.
15. Lecoindre, P., Cadore, J. L. La coloscopie chez les carnivores domestiques. *Pratique Médicale et Chirurgicale de l'Animal de Compagnie* 1991, 26: 119–125.
16. Hall, E. J., Rutgers, H. C., Schools, S. F. E. et al. Histiocytic ulcerative colitis in boxer dogs in the UK. *Journal of Small Animal Practice* 1994; 35: 509–515.
17. Valerius, K. D., Powers, B. E., McPherron, M. A. et al. Adenomatous polyps and carcinoma in situ of the canine colon and rectum: 34 cases (1982–1994). *Journal of the American Animal Hospital Association* 1997; 33: 156–160.
18. Church, M. Colorectal adenocarcinomas in dogs: 78 cases. *Journal of the American Veterinary Medical Association* 1987; 191: 727–730.