

<p><b>THE SIGNIFICANCE OF ARGON LASER IN PATIENTS WITH PERIPHERAL RETINAL BREAKS IN PREVENTING RETINAL DETACHMENT</b></p>		<p><b>Healthcare</b></p> <p><b>Keywords:</b> Retinal detachment; peripheral retinal breaks; rhegmatogenous; tractional; exudative; profilactive argon laser.</p>
---	--	--

<p><b>Brisilda Danaj</b></p>	<p>Ophthalmologist, International Clinic, Tirana, Albania</p>
<p><b>Ermal Simaku</b></p>	<p>Ophthalmologist, EYE clinic, University Hospital “Mother Theresa” Tirana, Albania</p>

**Abstract**

Retinal detachment is a risk to one's vision that occurs about 1 in 10,000 times. Prior to the 1920s, this disease was completely blinding. Restoration of retinal detachments has been much simpler over the past 50 years thanks to procedures like scleral buckling, pneumatic retinopexy, and vitrectomy. Rhegmatogenous, tractional, and exudative retinal detachments are the three types. When subretinal fluid accumulates between the retinal pigment epithelium and the neurosensory retina, retinal detachment occurs. During this phase, three things might occur. Breaking the retina is one way to let vitreous directly enter the subretinal region. This retinal detachment is rhegmatogenous. Rhegmatogenous retinal detachments are frequently brought on by trauma- or posterior vitreous-separated-induced retinal tears. The growth of membranes on the vitreous or retinal surface is a second mechanism. These membranes have the capacity to physically divide the retinal pigment epithelium from the neurosensory retina. A tractional retinal detachment is what this is. Proliferative retinopathy caused by sickle cell anemia, diabetes, or other conditions that neovascularize the retina can cause tractional retinal detachment. Proliferative vitreoretinopathy following trauma or surgery may also contribute to tractional retinal detachments. Fluid exuding from a mass lesion or an accumulation of subretinal fluid caused by inflammatory mediators are the third causes of retinal detachment. Serous or exudative retinal detachment is the term used to describe this mechanism. Sarcoidosis and choroidal neoplasms are two examples of inflammatory or exudative retinal disease processes that can cause serous detachments. Patients with aggressively spreading cancers, such as testicular cancer, may also have serous retinal detachments. A case study of a retinal detachment without a profilactive argon laser and a known peripheral retinal break is presented. The patient arrived at our clinic with symptoms of retinal detachment that had been present for two to three weeks, as well as peripheral retinal breaks that had been photographed eight months prior.

**INTRODUCTION**

Several mechanisms help the retinal pigment epithelium (RPE) stay attached to the neurosensory retina beneath it. Among these mechanisms is RPE metabolic activity, interdigitation of RPE microvilli and photoreceptor outer segments, as well as active subretinal fluid transport across RPE. These defense mechanisms become overworked during retinal detachment, separating the retinal pigment epithelial layer from the neurosensory (inner layers) retina.

When subretinal fluid accumulates between the retinal pigment epithelium and the neurosensory retina, retinal detachment occurs. There are three possible outcomes from this process. In one mechanism, the retina can rupture, allowing vitreous to enter the subretinal space directly. There has been a rhegmatogenous retinal detachment. Retinal detachments that are rhegmatogenous are most commonly caused by posterior vitreous detachment or trauma-induced retinal tears. Understanding the other primary causes of retinal detachment is crucial.

The growth of membranes on the vitreous or retinal surface is a second mechanism. These membranes have the ability to physically separate the neurosensory retina from the retinal pigment epithelium. A tractional retinal detachment is what this is. Proliferative retinopathy caused by sickle cell anemia, diabetes, or other conditions that neovascularize the retina can cause tractional retinal detachment. Surgically or traumatically induced tractional retinal detachments may also be a result of proliferative vitreoretinopathy.

Fluid exuding from a mass lesion or an accumulation of subretinal fluid caused by inflammatory mediators are the third causes of retinal detachment. Serous or exudative retinal detachment is the term used to describe this mechanism. Sarcoidosis and choroidal neoplasms are two examples of inflammatory or exudative retinal disease processes that can cause serous detachments. Patients with aggressively spreading cancers, such as testicular cancer, may also have serous retinal detachments.

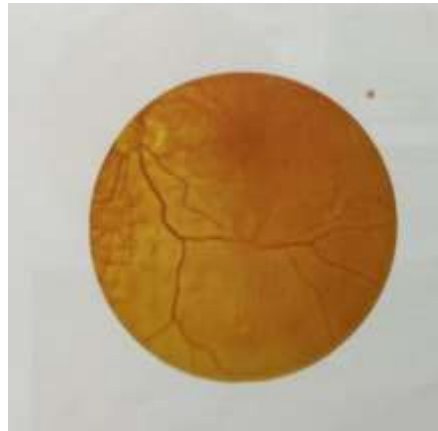


Figure 1. Retinal Detachment

### **Various Retinal Detachments Risk Factors**

The most typical type of retinal detachment, known as rhegmatogenous retinal detachment, can be caused by the vitreous gel pulling on and tearing the retina. Risk components may include the following:

- High myopia (nearsightedness);
- Eye trauma;
- Meridional Folds,
- Enclosed Ora Bays, and Peripheral Retinal Excavations;
- High myopia;
- Aphakia and Pseudophakia;
- Lattice degeneration;
- Age;
- Family history;
- History of retinal tear or detachment in the other eye.

## **Detachment of the tractional retina**

Many illnesses can cause the abnormal development of retinal blood vessels. Tractional retinal detachment is the result of scar tissue that develops as a result of these abnormal vessels pulling on the retina and tearing it away from the back wall of the eye. Another example of tractional detachment is when subretinal fluid, which is caused by scar tissue, builds up on the retina's surface and lifts the retina. These issues could be to blame:

- Diabetic retinopathy with proliferation
- Infectious or inflammatory conditions
- Premature Retinopathy (ROP)
- Sickle cell disease of the eye
- Vitreoretinopathy with proliferation

## **Detaching of the retinal exudates**

A buildup of fluid under the retina separates the retinal layers, resulting in exudative retinal detachment. There are no corresponding retinal tears. These issues could be to blame:

- Intractable hypertension
- Preeclampsia in expecting mothers
- Macular aging and degeneration
- Optic tumors
- Coats illness
- Various inflammatory conditions, such as posterior scleritis, that can affect the eyes are known as panuveitis.

## **Classification**

- Rhegmatogenous
- Tractional
- Exudative

## **Retinal Detachment with Rhegmatogeny**

Lincoff rules are frequently used to identify a definite retinal break in 90% -95% of RRDs. The rest are thought to have an occult break. If no break is found, the ophthalmologist must rule out all other possible causes of retinal elevation. Half of RRD patients have photopsias or floaters.

When associated with Schwartz-Matsuo syndrome, for example, intraocular pressure in the affected eye may occasionally be higher than in the unaffected eye. A Shafer sign, also known as "tobacco dust" due to the tiny collections of pigmented cells in the anterior vitreous, is a frequent finding. It usually has convex edges and contours, a corrugated appearance, especially in more recent RDs, and it undulates as the eye passes over it. Normal separation of the retina from the head of the optic nerve to the periphery occurs gradually. The retina, however, might seem smoother and thinner in advanced RRD.

Long-term RRD, particularly traumatic RRD with retinal dialysis, can also result in retinal macrocysts arising from the outer plexiform layer. RRD is almost always indicated by fixed folds connected to proliferative vitreoretinopathy (PVR). Although fluid shifting is possible, exudative RDs are more likely to encounter it. After an RRD has undergone surgical repair, PVR is the most frequent reason for failure. Membranes are formed on the inner and outer retinal surfaces as well as the vitreous face during PVR by the growth and migration of retinal pigment epithelial, glial, and other cells. When these membranes constrict, they result in equatorial traction, detachment of the nonpigmented epithelium from the pars plana, generalized retinal shrinkage, and the development of fixed retinal folds that frequently resemble stars. Retinal breaks that initially formed may reopen, new ones may develop, or a traction detachment may result. A PVR classification scheme was created to more accurately compare preoperative anatomy with postoperative outcomes. The three PVR grades (A, B, and C) in the classification represent varying levels of disease severity. Four categories of anterior and posterior involvement (CA, CP) are distinguished: anterior displacement, diffuse, circumferential, and focal. The severity of the pathology is expressed in clockhours.

### **Preventative Care for Retinal Breaks**

Any retinal break that allows vitreous fluid to pass through and separate the sensory retina from the RPE can cause an RD. Most retinal breaks and holes, however, do not result in a detachment. To reduce the risk of RD, the ophthalmologist may consider treating breaks in advance. Patient counseling must take into account the fact that the possibility of experiencing new tears or detachment is not entirely eliminated by treatment. Prophylactic laser treatment, photocoagulation, or cryotherapy is used to form a chorioretinal adhesion around each retinal break and prevent fluid from entering the subretinal space. When there is subretinal fluid, the treatment is administered in such a way that it completely encircles the affected area. When medical care is insufficient, vitreous traction may cause RD and horse shoe tears to advance. Treatment for lattice degeneration typically involves application around the lesion. Before advising prophylaxis, the ophthalmologist considers phakic status, refractive error, the state of the other eye, the presence of subretinal fluid, the patient's availability for follow-up testing, the size and location of the break, symptoms, family history, and residual traction. The discussion that

follows should only be used as a general guide because each patient's clinical circumstances and patient characteristics differ.

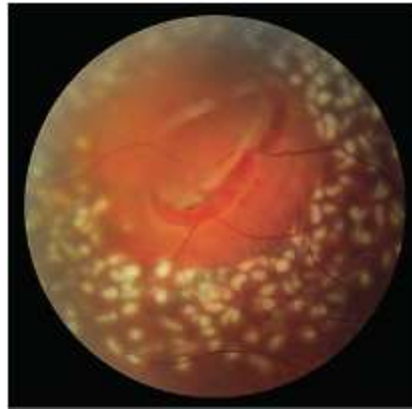


Figure 2. Asymptomatic horseshoe retinal tear treated with a recent laser retinopexy

A 360° laser barricade that caused more than three rows of light to medium white burns all around the retinal break.

### **Clinical Qualities**

Retinal detachment symptoms can manifest differently in different people. It depends on how severe it is; you're more likely to experience symptoms if more of the retina separates. Sudden symptoms like these may be present with a detached retina:

- Experiencing light flashes (photopsia)
- Noticing floaters, which are flecks, threads, dark spots, and wavy lines that move across your field of vision, on a regular basis.
- Your peripheral vision (side vision) dims.
- A portion of your field of vision becoming obscured or cast in shadow.

### **History of the diagnosis**

In cases where significant photopsias and/or persistent new floaters have recently developed, a retinal tear that could result in a retinal detachment should be suspected.

### **Physical Examination**

When assessing patients with retinal detachment symptoms, the pre-dilated ophthalmic examination includes critical elements such as checking the intraocular pressure, visual field, pupillary health, and visual acuity. There will be more color vision testing done. Before dilating, the anterior segment should be examined with a slit lamp. It is crucial to check the anterior vitreous for pigment (Schaffer's sign) or vitreous hemorrhage. The oraserrata should be observed during a thorough fundus examination that incorporates indirect ophthalmoscopy, scleral depression, and these techniques. It is possible to document the detachment with a thorough drawing that shows where the retinal pathology is located.

B-scan ultrasound should be used to evaluate the retina and vitreous if there is no view to the posterior pole, as in situations where there has been hemorrhage or media opacity.

### **Investigations**

- fundus photography in wide-field,
- ophthalmic coherence tomography, and
- an ultrasound B-scan.

### **Rhegmatogenous retinal detachment management**

The following are the surgical principles for RD:

- Identify every retinal break.
- Irritate the chorioretinal tissue around each fracture.
- Seal any retinal tears.

The most important aspect of managing RD is a thorough retinal examination. To close retinal breaks, the RPE and choroid must come into contact with the retina for long enough to form a chorioretinal adhesion that will tightly close off the subretinal space. One of three methods, including scleral buckling, vitrectomy, or pneumatic retinopexy, is typically used in this procedure. Surgery is frequently done quickly for acute, macula-on RDs with symptoms. Prior to surgery, the risk of subretinal fluid extension into the fovea can be reduced by limiting patient eye movement, especially saccadic movements made while reading, and by positioning the head so that the RD is in a dependent position. In contrast, treatment might be put off in eyes with persistent RDs and pigmented demarcation lines.

### **Case Study 1**

D.H., a 62-year-old man, arrived at the International Clinic in Tirana, Albania, three weeks after experiencing vision darkening in the superior-nasal region. With a superior nasal part darkening, BCVA was 20/20 in OD and 8/20 in OS. There was no trauma or other disease history. A small temporal retinal tear in OS and an inferior-temporal retinal detachment with the macula on were both visible in the fundus oculi. Around the retinal tear, there were no argon laser signs visible. OD was ordinary. For this patient, a photo of the fundus was taken (figures 3, 4, 6).

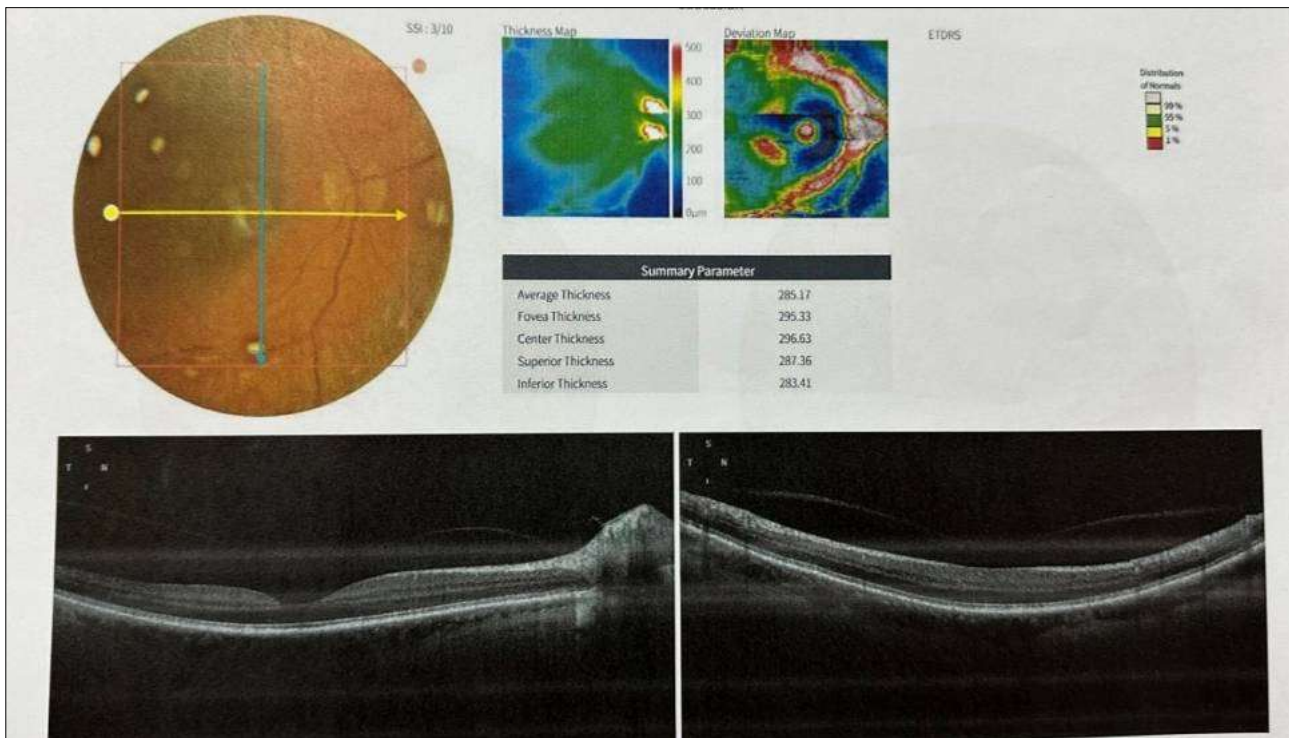


Figure 3. OD

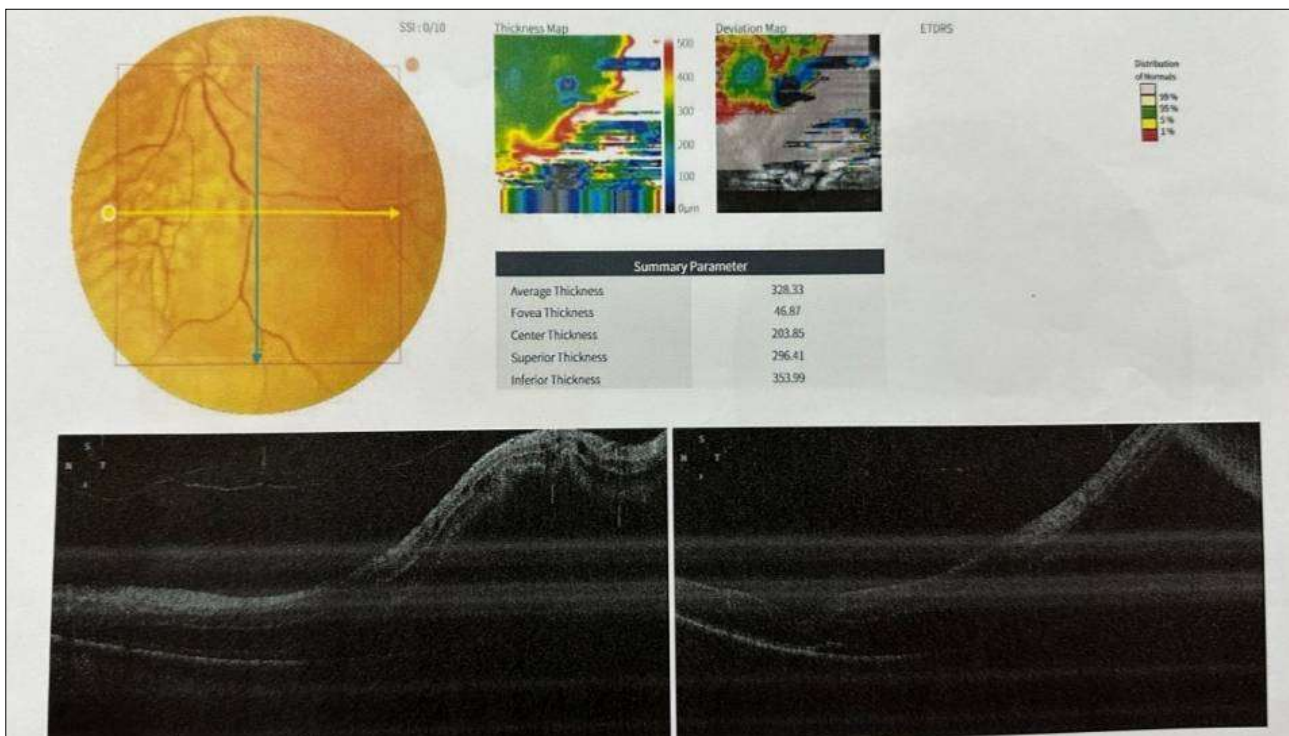


Figure 4. OS





Figure 5. OS

The patient mentioned that eight months prior, he had undergone an ophthalmological examination and discovered that his left eye had a retinal tear. Photo fundus was used to document this discovery. (Figures 6 and 7) The patient stated that no preventative laser procedure for retinal tear was carried out.

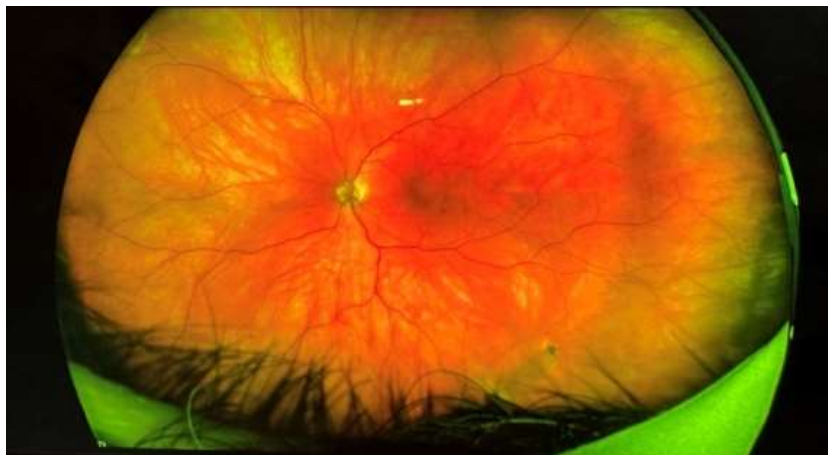

Figure 6.

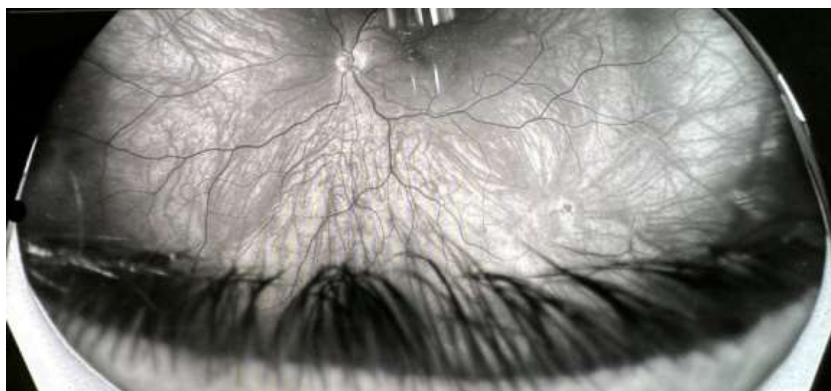


Figure 7.



## Discussion

The Rochester Epidemiology Project found that in a predominantly White population, RRD has an incidence rate of 12.6 per 100,000 people annually. High myopia, a family history of RD, a felloweye retinal tear or detachment, a recent vitreous detachment, pseudophakia, trauma, peripheral high-risk lesions, and vitreoretinal degenerations are a few conditions that can increase or decrease a person's risk. A definite retinal break can be identified in 90%–95% of RRDs, frequently with the aid of Lincoff rules. The remaining are assumed to have an occult break.

Retinal laser therapy is essential for treating and preventing a detached retina (RD). In order to prevent rhegmatogenous RD (RRD), laser retinopexy is used to fuse the retina to the underlying retinal pigment epithelium and choroid through photocoagulation (PC). By laser PC demarcating the RD's advancing edge, it is also possible to contain and confine smaller, more slowly progressing RDs, preventing spread and obviating the need for major surgery. It can also be used to make thermal choroidal holes to permit external drainage of subretinal fluid during RD repair. These procedures include pars planavitrectomy (PPV) and scleral buckling (SB), which require the sealing of retinal tears.

Only when a retinal detachment has a rhegmatogenous origin would laser retinopexy be effective. Exudative retinal detachments have been treated using several laser mechanism types. Usually, the posterior vitreous detachment (PVD), a complete or partial separation of the posterior vitreous cortex from the internal limiting membrane of the retina, occurs before the retinal rupture that causes the retinal detachment. The majority of retinal fractures that result in retinal detachment are caused by the development of vitreous traction at sites of considerable vitreoretinal adhesion.

Only approximately 4% of people have retinal fractures, compared to almost 70% who get posterior vitreous detachments. The typical age range for the development of PVD is 45 to 65, but trauma and myopia may be risk factors for an earlier onset. Additional risk factors include aphakia, pseudoaphakia, cataract surgery, lattice retinal degeneration, uveitis, retinitis, and genetic vitreoretinopathies. Another risk factor for retinal detachment is a large retinal rip, which is described as a full-thickness neurosensory retinal break that extends three clock hours (90°) or more around the circumference of the globe and has rolled edges. According to extensive population-based studies, 1.5% of rhegmatogenous retinal detachments are affected by it, and bilateral cases account for 12.8% of all cases. Trauma, inherited vitreoretinopathies, and extreme myopia are less common causes of big retinal tears and are therefore less common causes. Giant non-traumatic retinal tears are frequently accompanied by severe vitreoretinal disease in the next eye. 59% of fellow eyes get retinal tears, and 17% of these cases develop to retinal detachment.

Under these circumstances, prophylactic treatment may be taken into account; however there is currently no concrete proof of its effectiveness. Similar to this, there isn't enough solid evidence to say that using a prophylactic laser to treat viral retinitis stops the spread of the condition and prevents retinal detachment.

## Conclusion

- Retinal breaks are the leading risk factors for retinal detachment
- Other major risk factors include family history, lattice degeneration, myopia, pseudophacia, giant retinal tears etc.
- Retinal detachment presents with photopsia, rapid onset of darkening of peripheral vision, flashes
- Diagnosis is clinical (history and physical examination) and imaging investigation (OCT, B-Scan)
- Ophthalmologists consider prophylactic treatment of breaks in an effort to reduce the risk of RD. The goal of prophylactic laser treatment for photocoagulation or cryotherapy of retinal breaks is to create a chorioretinal adhesion around each retinal break to prevent fluid from entering the subretinal space.

## References

- American Academy of Ophthalmology. Retinal detachment.  
<https://www.aao.org/education/image/retinal-detachment-4> Accessed July 26, 2019.
- Haimann MH, Burton TC, Brown CK. Epidemiology of retinal detachment. Arch Ophthalmol. Feb 1982; 100(2): 289-92.
- Byer NE. Natural history of posterior vitreous detachment with early management as the premierline of defense against retinal detachment. Ophthalmology. 1994; 101(9): 1503–1514.  
<https://www.mayoclinic.org/diseases-conditions/retinal-detachment/symptoms-causes/syc-20351344>, 2022.
- Van Overdam KA, BettinkRemeijer MW, Klaver CC, Mulder PG, Moll AC, van Meurs JC. Symptoms and findings predictive for the development of new retinal breaks. Arch Ophthalmol 2005; 123(4): 479–484 <https://www.aao.org/eye-health/diseases/detached-torn-retina>, 2022.
- Byer NE. Lattice degeneration of the retina.SurvOphthalmol. 1979; 23(4): 213–248.
- Byer NE. Longtermnatural history of lattice degeneration of the retina.Ophthalmology. 1989; 96(9): 1396–1402.
- Byer NE. Cystic retinal tufts and their relationship to retinal detachment. Arch Ophthalmol.1981; 99(10): 1788–1790. <https://www.aao.org/eye-health/diseases/what-is-lattice-degeneration>, 2022.

- Engstrom RE Jr, Glasgow BJ, Foos RY, Straatsma BR. Degenerative diseases of the peripheral retina. In: Tasman W, Jaeger EA, eds. *Duane's Clinical Ophthalmology on DVD-ROM*. Vol 3. Lippincott Williams & Wilkins; 2013: chap 26. <https://www.asrs.org/patients/retinal-diseases/26/retinal-tears>, 2023
- Erie JC, Raecker MA, Baratz KH, Schleck CD, Burke JP, Robertson DM. Risk of retinal detachment after cataract extraction, 1980–2004: a populationbased study. *Ophthalmology* 2006; 113(11): 2026–2032.
- Folk JC, Arrindell EL, Klugman MR. The fellow eye of patients with phakic lattice retinal detachment. *Ophthalmology*. 1989; 96(1): 72–79.
- Johns Hopkins medicine, retinal detachments site CHAPTER 16: Retinal Detachment and Predisposing Lesions 385.
- Han DP, Lean JS. Proliferative vitreoretinopathy. In: Albert DM, Miller JW, Azar DT, Blodi BA, eds. *Albert & Jakobiec's Principles and Practice of Ophthalmology*. Saunders; 2008: chap 183. <https://my.clevelandclinic.org/health/diseases/10705-retinal-detachment>, 2023.
- Rowe JA, Erie JC, Baratz KH, et al. Retinal detachment in Olmsted County, Minnesota, 1976through 1995. *Ophthalmology*. 1999; 106(1): 154–159.
- Wilkinson CP. Interventions for asymptomatic retinal breaks and lattice degeneration for preventing retinal detachment. *Cochrane Database Syst Rev*. 2014; (9): CD003170.
- Reed D, Garg AJ. Degenerative retinoschisis. In: Schachat AP, Wilkinson CP, Hinton DR, Sadda SR, Wiedemann P, eds. *Ryan's Retina*. 6th ed. Elsevier/Saunders; 2018: chap 100.
- American Academy of Ophthalmology. Multiple pages reviewed. Detached Retina <https://www.aaopt.org/eye-health/diseases/detached-torn-retina> Accessed 6/9/2023
- American Optometric Association. Retinal Detachment (<https://www.aoa.org/healthy-eyes/eye-and-vision-conditions/retinal-detachment?sso=y>). Accessed 6/9/2023.
- American Society of Retina Specialists. Retinal Detachment. <https://www.asrs.org/patients/retinal-diseases/6/retinal-detachment>) Accessed 6/9/2023.
- Blair K, Czyz CN. Retinal Detachment <https://www.ncbi.nlm.nih.gov/books/NBK551502/>). 2022 Dec 26. In: StatPearls [Internet]. Treasure Island, FL: StatPearls Publishing; 2023 Jan-. Accessed 6/9/2023.
- National Eye Institute (U.S.). Retinal Detachment. <https://www.nei.nih.gov/learn-about-eye-health/eye-conditions-and-diseases/retinal-detachment> Accessed 6/9/2023.
- Retinal physician article, Retinal Breaks: Clinical Course and Outcomes after Retinopexy Freeman HM. Fellow eyes of non-traumatic giant retinal breaks. In: Ryan SJ, editors. *Retina*, vol. 3. St. Louis: Mosby; 2001. pp. 2366–70.
- Johnson MW. Posterior vitreous detachment: evolution and role in macular disease. *Retina*. 2012; 32(Suppl 2): S 174–178.
- Combs J, Welch R. Retinal breaks without detachment: natural history, management, and long-term follow-up. *Trans Am Ophthalmol Soc*. 1982; 80: 64–97.
- Snead MP, Snead DR, James S, Richards AJ. Clinicopathological changes at the vitreoretinal junction: posterior vitreous detachment. *Eye (Lond)*. 2008; 22(10): 1257–62.